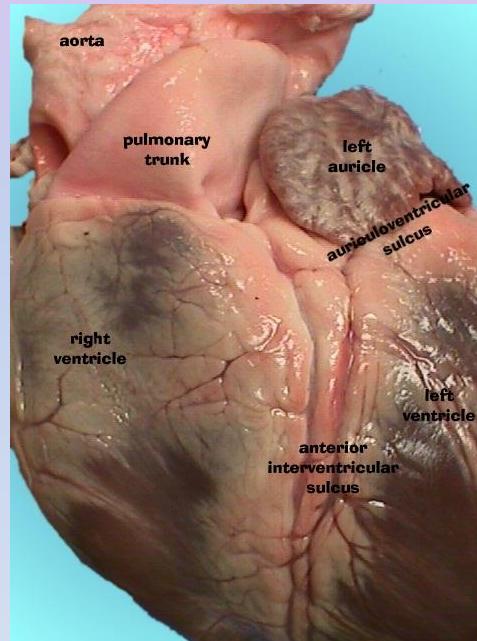
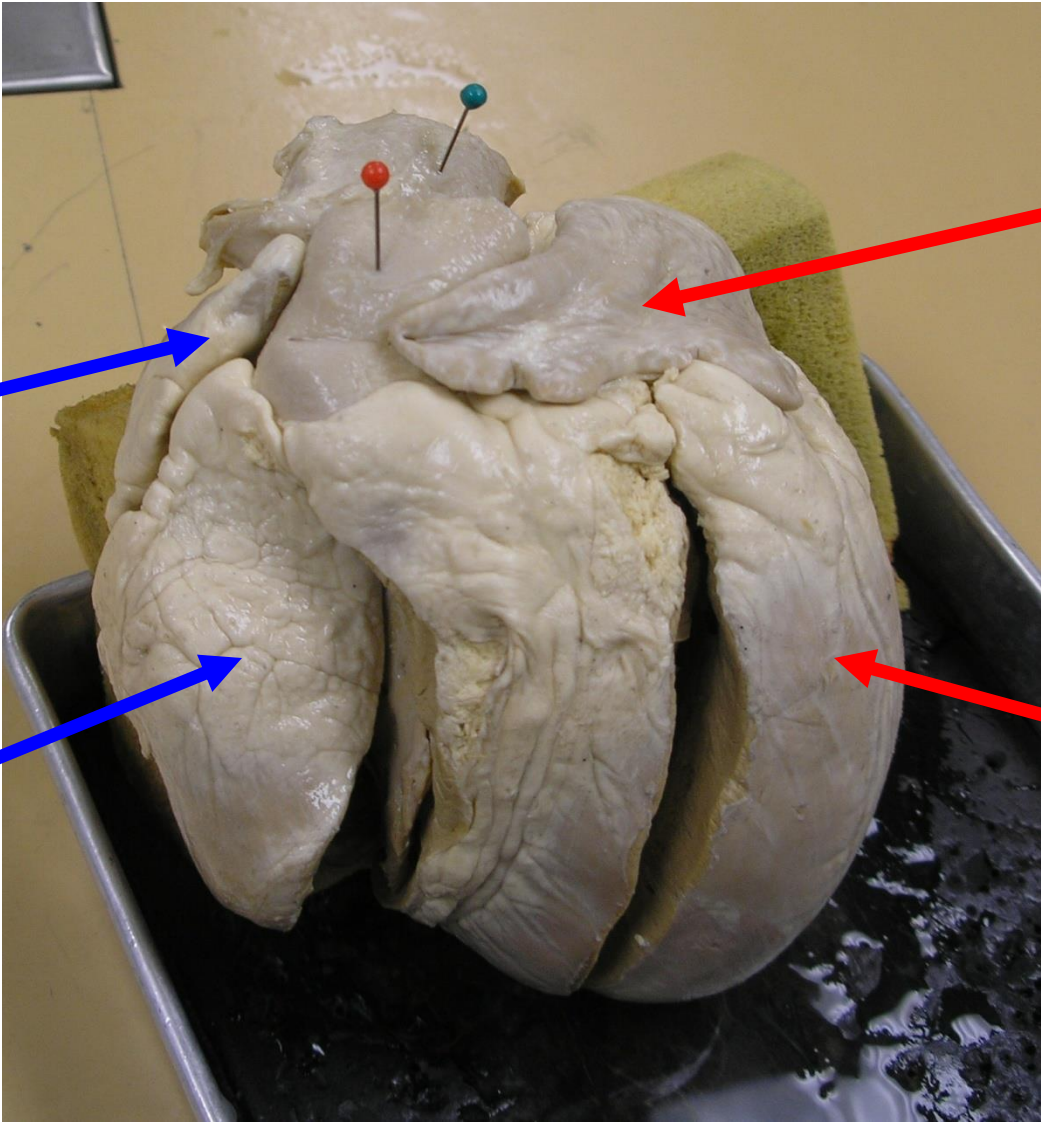


Virtual Pig Heart Dissection



Red Pin = Pulmonary Artery
Blue Pin = Aorta



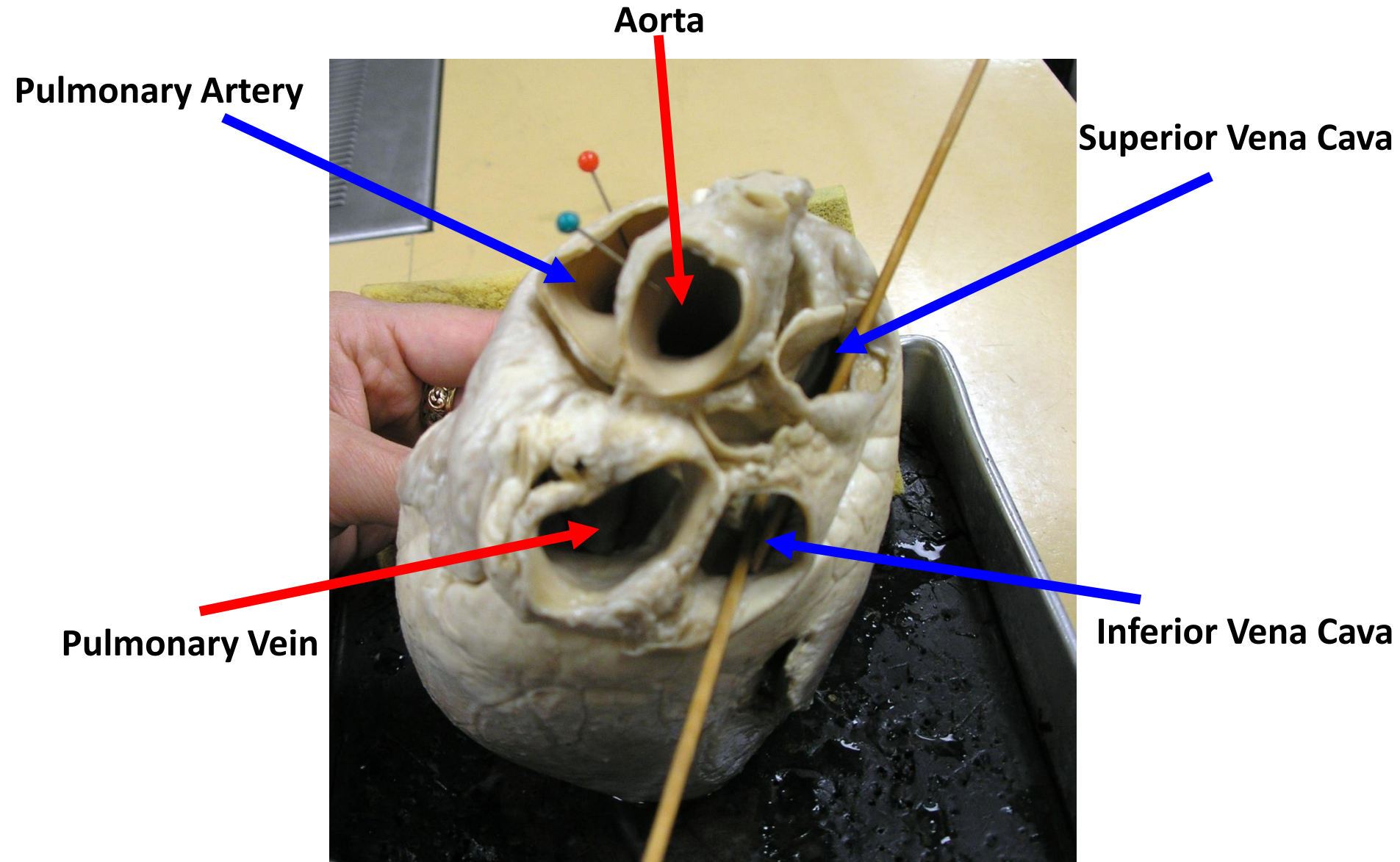
Right Atrium

Left Atrium

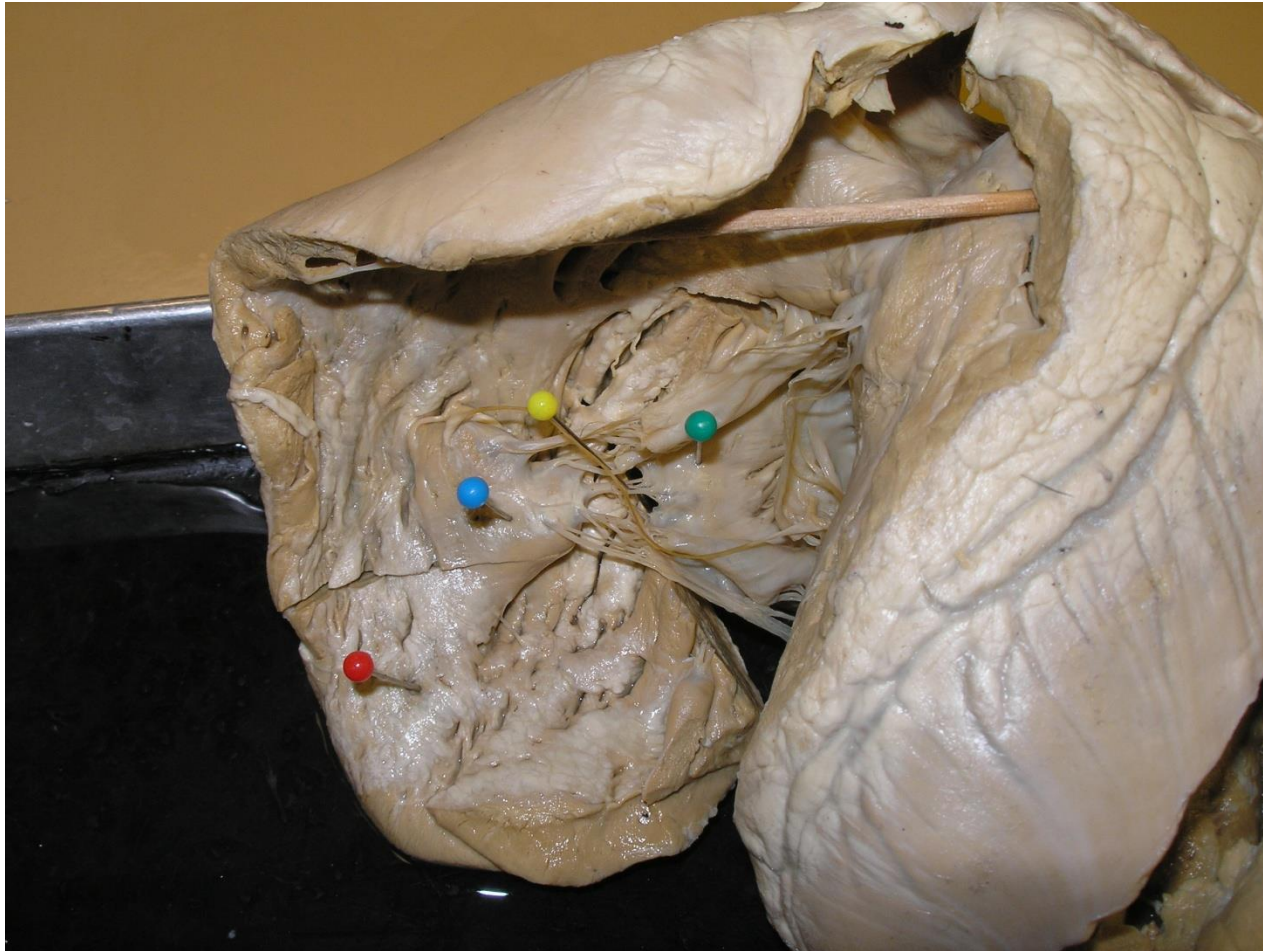Right Ventricle

Left Ventricle

Posterior View of the Pig Heart



Open Right Ventricle



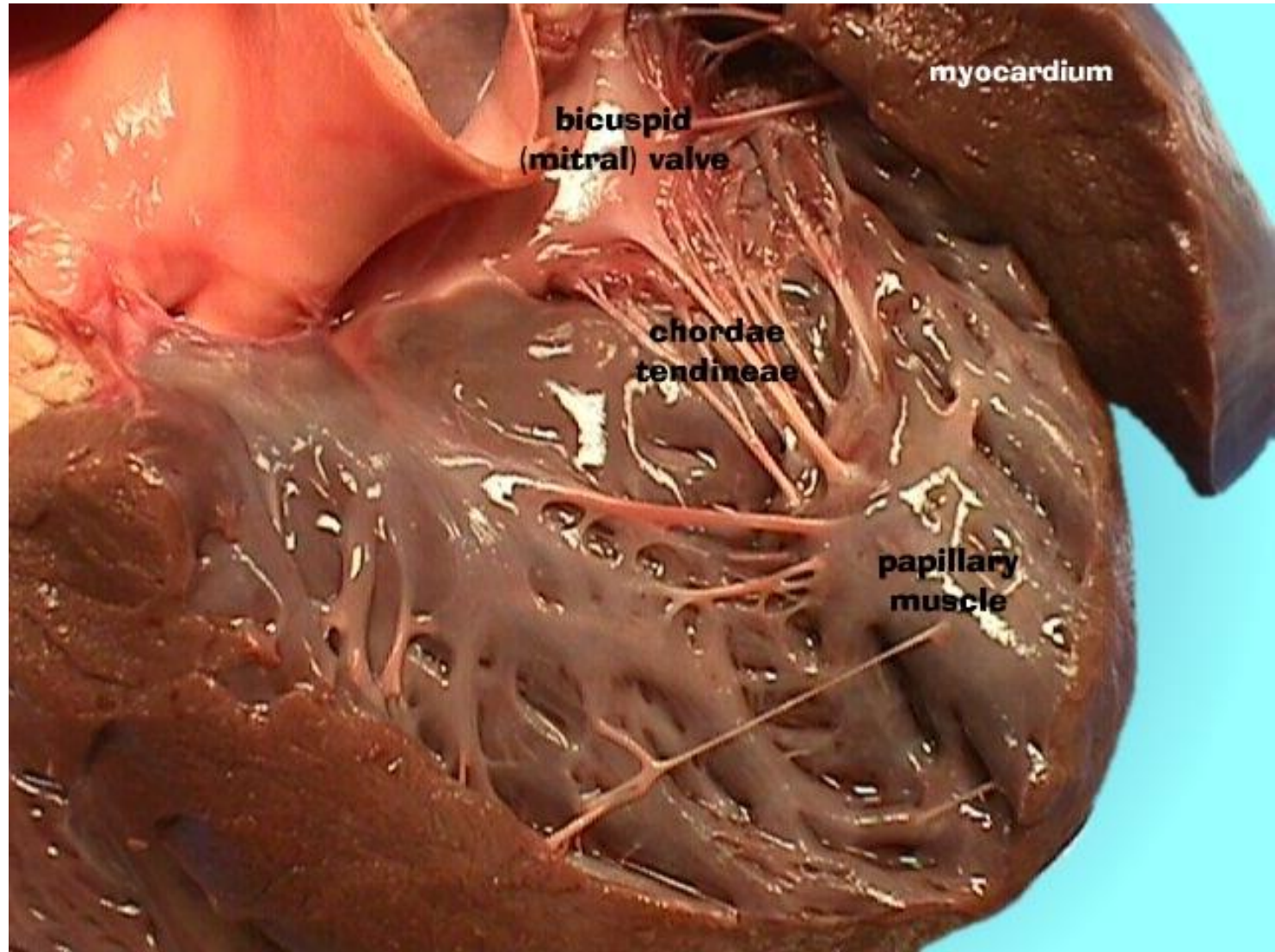
Green Pin = Tricuspid or Right Atrioventricular Valve

Yellow Pin = Chordae Tendinae

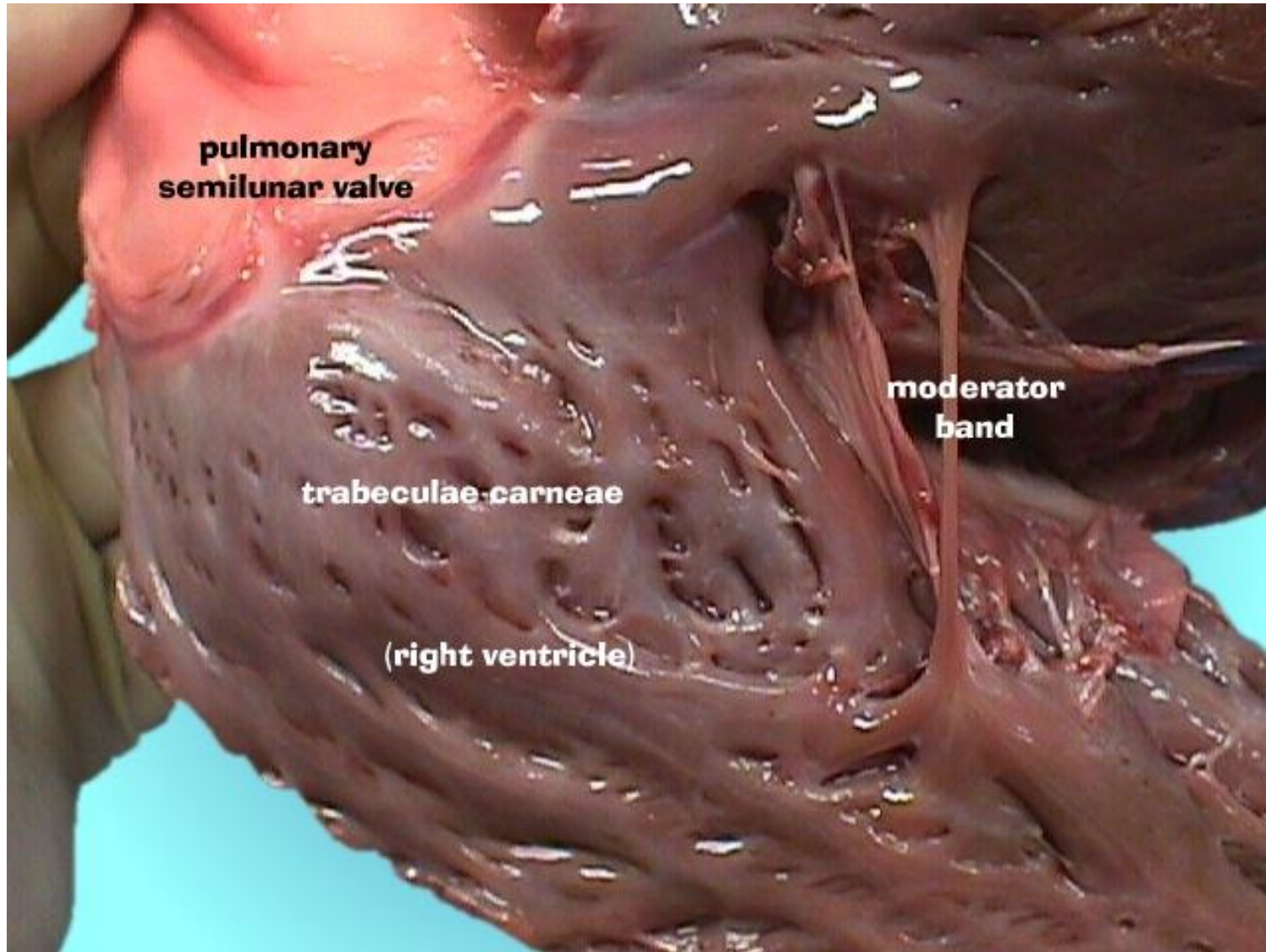
Red Pin = Trabeculae Carneae

Blue Pin = Papillary Muscle

Open Left Ventricle



Open Right Ventricle



Split Aorta with a good view of the Aortic Semilunar Valve

